

Restoration of fractured teeth: Extrusion Simplified

Sushil Kumar, MDS, MOrth RCSED*

Rekha Sharma MDS**

Subgingival or subcrestal root fractures provide an unsatisfactory situation for restoring the remaining tooth. Provided a root is long enough to support a post crown, orthodontic extrusion can be a useful treatment option to provide sufficient supra-gingival tooth tissue. In such cases however the main concern of patient is restoration of fractured teeth and they are not really keen about undergoing full orthodontic mechanotherapy for orthodontic extrusion. Provided the occlusion and alignment of remaining teeth is satisfactory, the method describes below a fast and simple method for orthodontic extrusion of teeth.

PROCEDURE

The fractured teeth are endodontically treated and posts are cemented in to the roots. The upper and lower impressions are taken. Appliance is fabricated using premium plus 0.016" stainless steel wire A J wilcock pty. Ltd., 45 yea road, Whittlesea, Vic 3757 Australia on upper model using 139 no. bird beak pliers., Wire bending

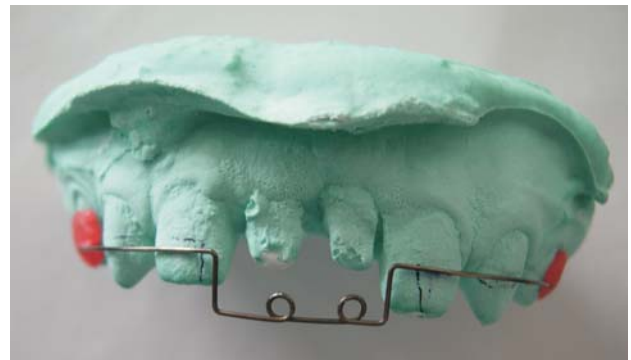involves adaptation of wire on the buccal surface of 2-3 teeth distal to fractured teeth (to provide adequate anchorage) Step down bends are placed distal to fractured teeth for more effective extrusion. One coil is placed below each fractured tooth (To decrease the load deflection rate and to serve as site for application of force)(Fig. 01).

The appliance is directly bonded on the anchor teeth using light cured composite resin (Fig. 02).

The appliance is activated by tying a 0.010" dead soft pre-stretched ligature wire Ortho Organizers Inc., 1619, S. Rancho Santa Fe Rd., San Marcos, CA 92078, USA from each coil to each post on fractured tooth (Fig. 03).

Significant extrusion occurs in 4 weeks as evident

Fig.01: Appliance fabricated on Maxillary Cast



Author's Affiliation: *Reader, Department of Orthodontics, PDM Dental College & Research Institute, Sarai Aurangabad, Bahadurgarh Haryana - India, **Professor, Department of Orthodontics, PDM Dental College & Research Institute, Sarai Aurangabad, Bahadurgarh Haryana.

Rprint's request: Sushil Kumar, 150/21, Panchsheel Colony, Sonipat, Haryana State 131 001, India, Phone: 91 9416486808, Email: docshilu@yahoo.com.

(Received on 25.03.2011, Accepted on 25.03.2011)

Fig.02: Appliance bonded in mouth

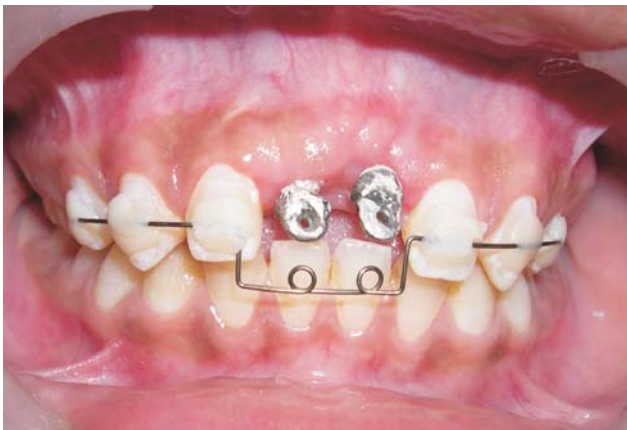

Fig. 04B: Post-extrusion intra oral frontal photograph

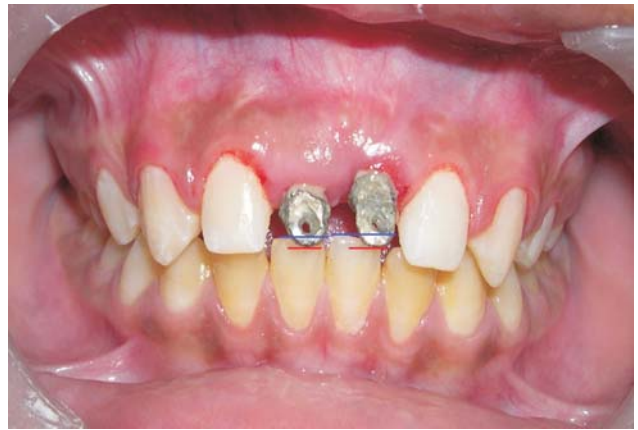

Fig. 03: Appliance activated by tying ligature wire

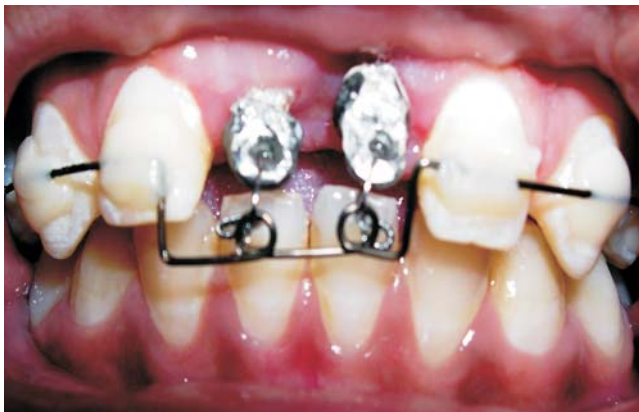

Fig.05A: Pre-treatment intra oral periapical radiograph

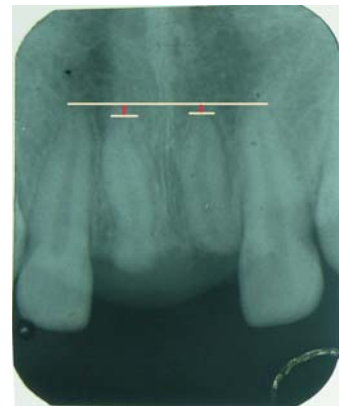


Fig.04A: Pre-extrusion intra oral frontal photograph

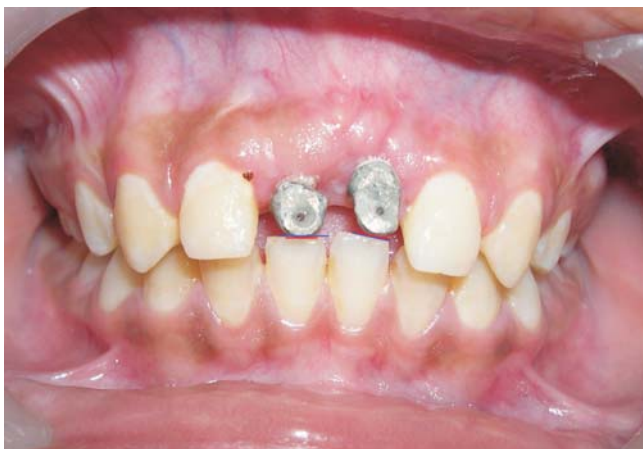

Fig. 05B: Post-extrusion intra oral periapical radiograph

